

Optical Assessment of Ex-vivo Tumor Margins During Breast Conserving Surgery

Torre Bydlon¹ and Stephanie Kennedy¹, J. Quincy Brown¹, Lisa Richards¹, Marlee Junker¹, Lee Wilke², Joseph Geradts³, Bill Barry⁴, Nimmi Ramanujam¹

1 – Biomedical Engineering Department, Duke University; 2 – Department of Surgery, Duke University Medical Center; 3 – Department of Pathology, Duke University Medical Center; 4 – Department of Biostatistics and Bioinformatics, Duke University

Fitzpatrick Institute
for Photonics

Motivation

Breast cancer is one of the most common cancers among American women. The American Cancer Society estimated that in 2008, 182,460 women in the United States were diagnosed with invasive breast cancer¹. As many as 30-70% of patients undergoing breast surgery will require additional surgeries due to a malignant surgical margin diagnosed post operatively². Women who undergo repeat surgeries are typically subject to pain, suffering, and disfigurement. Optical spectroscopy can quantify tissue composition and has the potential to reduce surgical re-excision rates across the nation.

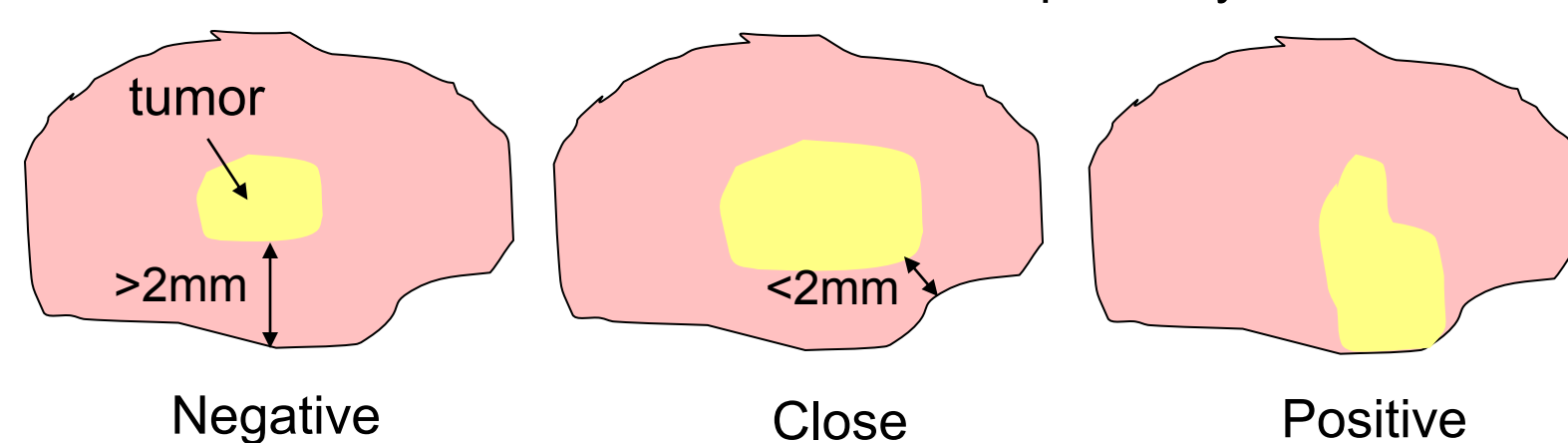
Breast Cancer

Current Treatment Steps:


1. Screening mammogram
2. Image guided needle biopsy
3. Chemotherapy
4. Surgery (lymph node dissection, mastectomy, breast conserving surgery)
5. Radiation

Breast Conserving Surgery = A lumpectomy or partial mastectomy. The surgeon attempts to excise the tumor along with a margin of normal tissue.

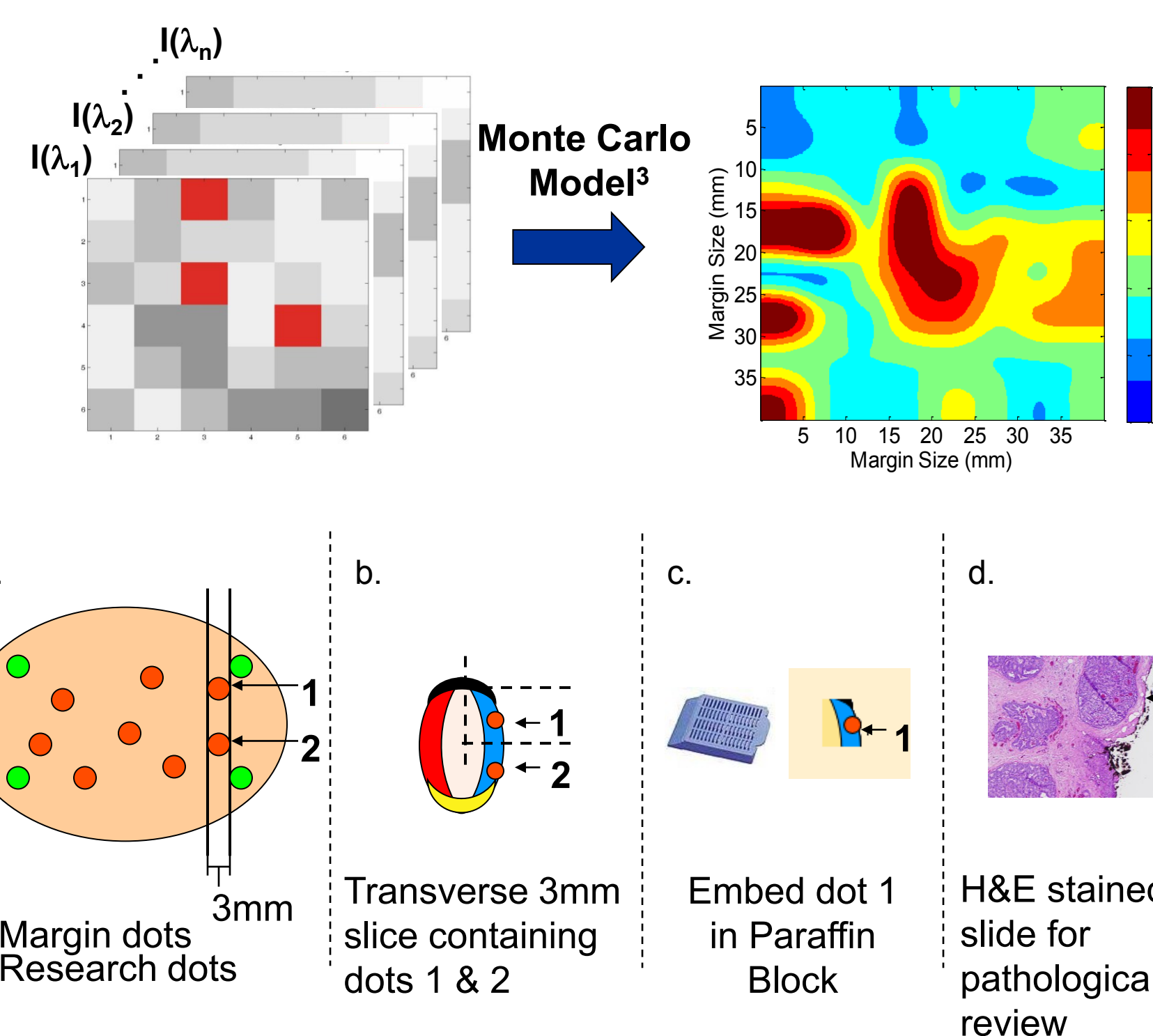
Cross Sectional View of Lumpectomy



Methods



- Patients undergoing breast conserving surgery are consented under an IRB approved protocol.
- 10-15 minutes after the lumpectomy specimen has been removed it is oriented in a plexi-glass box for optical assessment.



- The fiber optic probe images an area of ~1cm x 3cm.
- The entire specimen is measured with multiple placements.
- 6-10 holes (sites) are inked and correlated with specific pathological diagnosis along with a margin level diagnosis.
- The amount of blood, fat, and the size and density of the cell nuclei can be extracted from each measurement.
- These parameters were used to create images of the entire measured tumor margin.
- Optical data were evaluated on a site level and margin level, to evaluate the ability of the device to recognize positive sites and margins.

Site Level and Margin Level Sample Sizes

	Positive	Negative
# of Patients	43	51
# of Margins	50	72
# of Sites	36	461

Results

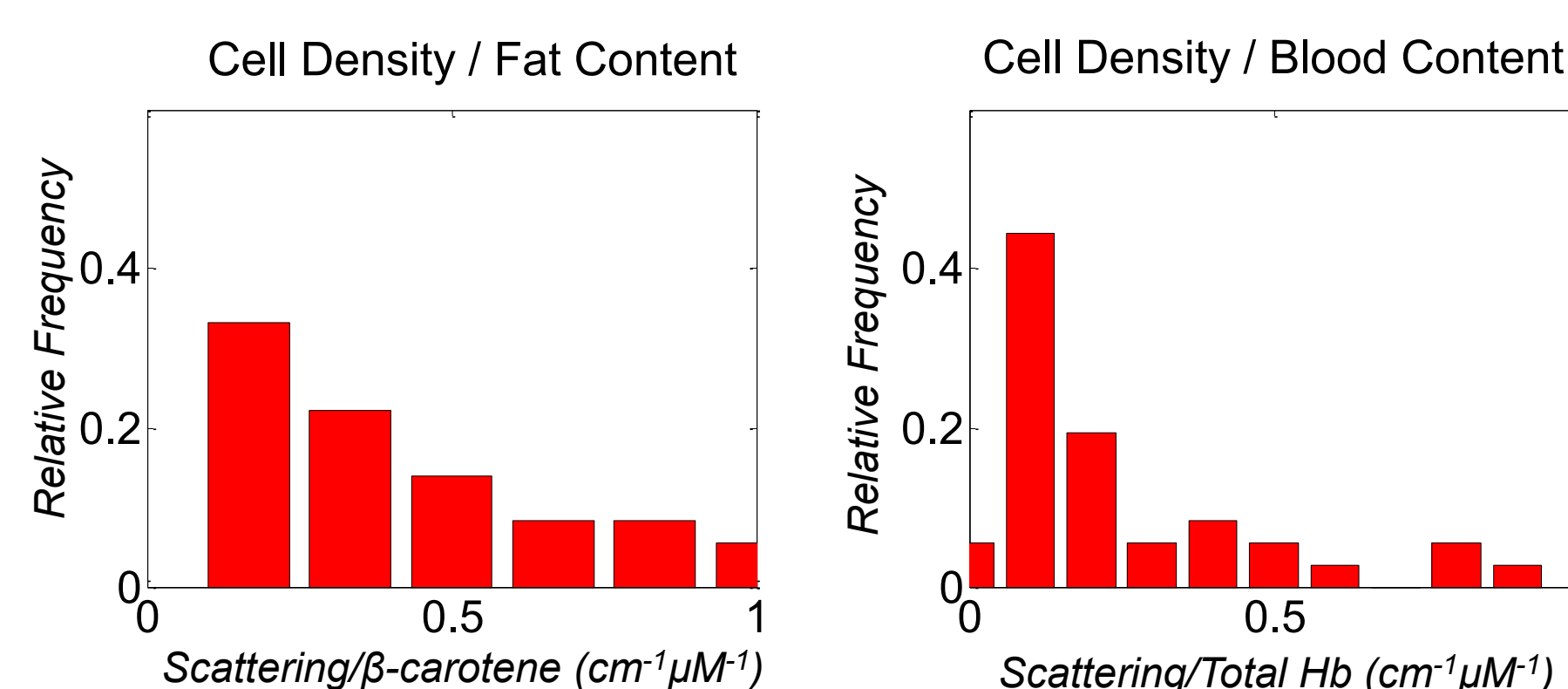
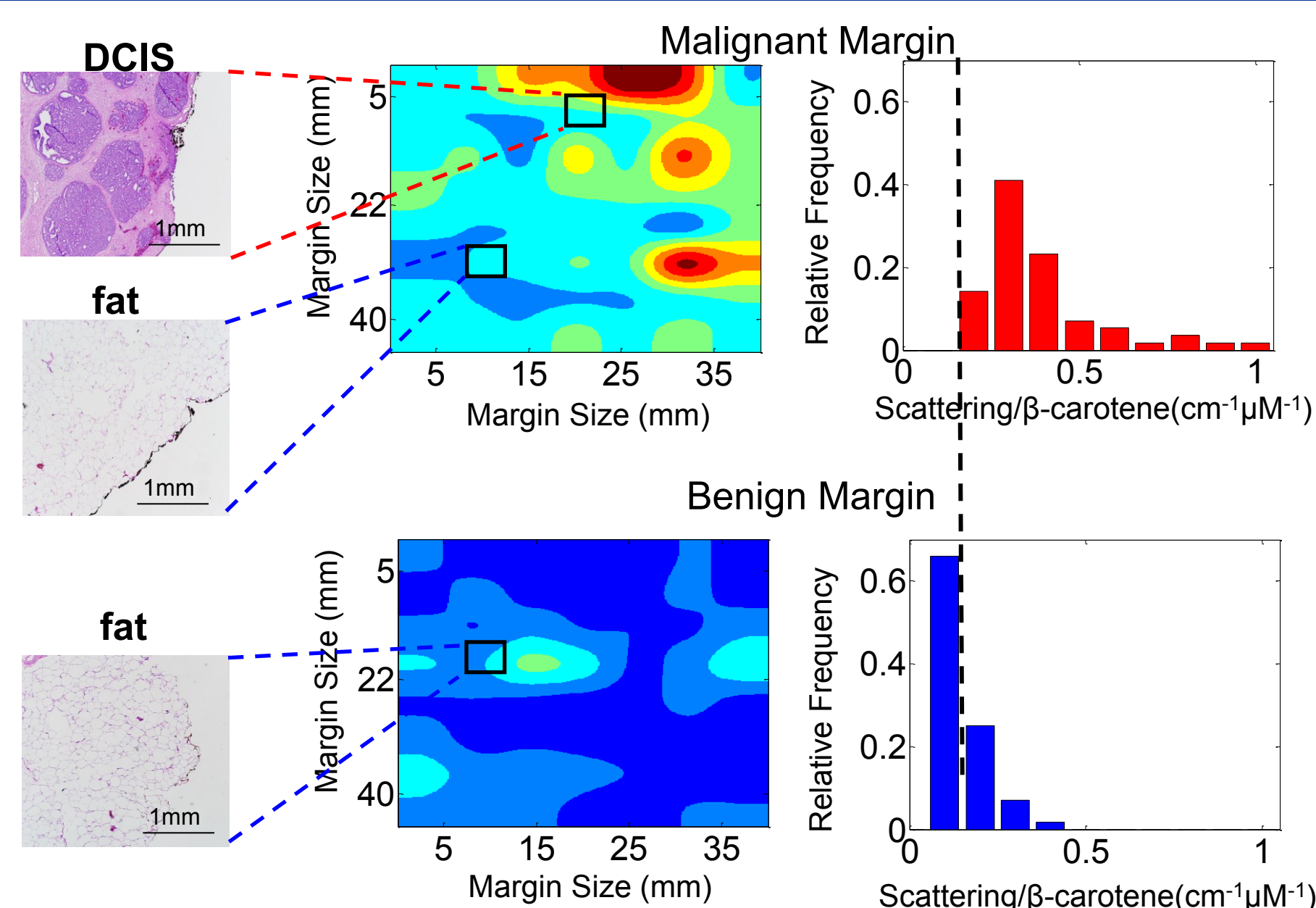


Figure 2. Histograms of the ratio of cell density to fat content and cell density to blood content from all positive (malignant) sites. The site level distribution confirms the ranges seen in the margin level histogram, providing a basis for algorithm development.

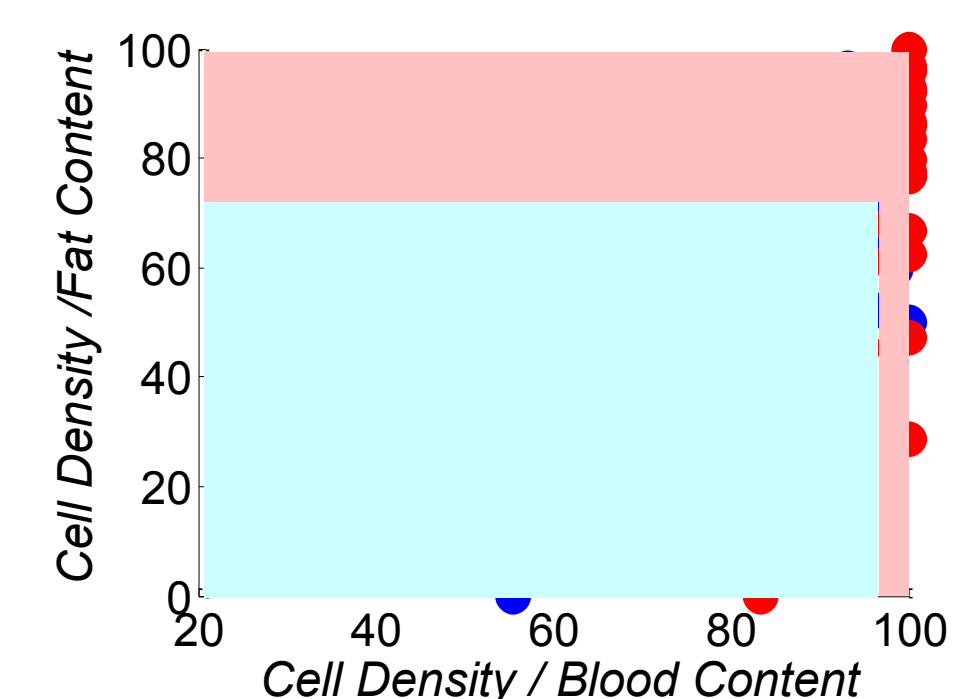


Figure 3. A plot of the ratio of cell density to blood content versus the ratio of cell density to fat content for 34 positive (red) and 21 negative (blue) margins. The light blue area denotes the region where our algorithm would diagnose a margin to be negative and the pink area would be positive.

Figure 1. Optical images and histograms that show the ratio of cell density to fat content of a malignant and benign margin. Two sites are shown on the malignant margin, one that contained Ductal Carcinoma In Situ (DCIS) and another that consisted entirely of fat cells.

Clinical Impact

	PROBE ONLY		SURGEON ONLY		SURGEON + PROBE	
	Path-Positive	Path-Negative	Path-Positive	Path-Negative	Path-Positive	Path-Negative
Positive	27	7	19	16	32	16
Negative	7	14	15	5	2	5
Total	34	21	34	21	34	21
	Sensitivity = 80% Specificity = 67%		Sensitivity = 56% Specificity = 24%		Sensitivity = 94% Specificity = 24%	

Retrospectively, if the margins called positive by either the surgeon or probe, had been re-excised this would result in fewer women having to come back for an addition surgery.

Discussion and Conclusions

Preliminary results show promise for reducing re-excision rates. Currently, simple statistics and a 2 variable multivariate model are used for classification. In the future, we will investigate the use of more complicated models to predict the probability of cancer based on these and other extracted optical properties. Already, the dual use of the probe with the surgeon's judgment/standard of care shows a significant reduction in the required number of re-excision surgeries. This could prevent unnecessary psychological and physical pain as well as the stress of additional financial burdens and reduce local recurrence.

References:
1. Society, A.C. 2008 [cited; Available from: http://www.cancer.org/docroot/CRI/CRI_2_1x.asp?dt=5].
2. Jacobs, L., Positive margins: the challenge continues for breast surgeons. Ann Surgical Oncology, 2008, 15(5): p. 1271-2.
3. J. App. Opt. 45(5): p. 1062-1071, 2005

